


**PEDIATRIC UROLOGY CASE REPORTS**

ISSN 2148-2969

<http://www.pediatricurologycasereports.com>**Multiple congenital polyps of the verumontanum in a boy: A case report****Luiz G. Freitas Filho<sup>1</sup>, Fabiana S Diostenes<sup>2</sup>, Natasha Mourão<sup>2</sup>, Nilton Crepaldi Vicente<sup>2</sup>**<sup>1</sup>Department of Pediatric Urology, Federal University of São Paulo and Hospital Santa Marcelina, Brazil<sup>2</sup>Department of Pediatric Surgery, Pontifícia Universidade Católica de Campinas, Brazil**ABSTRACT**

Congenital urethral polyps are a rare cause of obstructive urinary symptoms in childhood. The diagnosis is usually made by ultrasonography, voiding cystourethrogram, and urethrocystoscopy. We report the case of a 7-year-old boy with multiple congenital polyps of the verumontanum, who had symptoms of abdominal pain, urinary tract infection and nocturnal enuresis, and whose symptoms totally disappeared following electrofulguration of the polyps.

**Key Words:** Polyps, urethra, verumontanum, voiding dysfunction.

*Copyright © 2019 pediatricurologycasereports.com*

Correspondence: Dr. Luiz G. Freitas Filho,  
Rua Batista Cepelos 87 – ap 6104109-120 São Paulo.

E mail: [luizfreitasepm@gmail.com.br](mailto:luizfreitasepm@gmail.com.br)

ORCID ID: <https://orcid.org/0000-0003-2087-5878>

Received 2019-02-20, Revision 2019-03-14

Accepted 2019-03-21

Publication Date 2019-05-01

cystourethrogram) and cystoscopy [2,4]. We report the case of a 7-year-old boy with multiple congenital polyps of the verumontanum who presented with repeated urinary tract infections, abdominal pain and nocturnal enuresis.

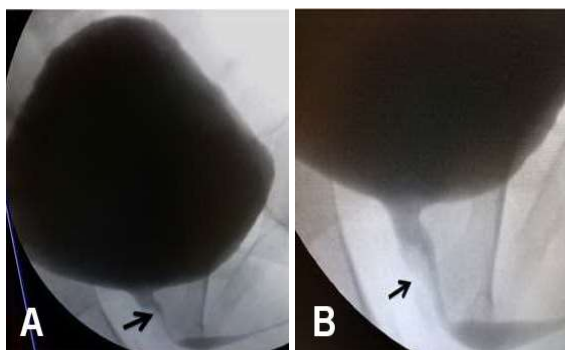
**Introduction**

Although congenital urethral polyps are rare in pediatric age groups, they may cause various morbidities such as intermittent obstruction, obstructive voiding complaints, acute urinary retention, urinary infection, bilateral ureterohydronephrosis and hematuria [1,2]. In general, they are found proximal to the membranous urethra, in the form of a single polyp and only rarely as multiple separate polyps. They are benign mesodermal tumors, more common in boys, and are not known to undergo malignant degeneration [3]. In these cases, the diagnosis is usually made by radiographic imaging (eg, ultrasound, voiding

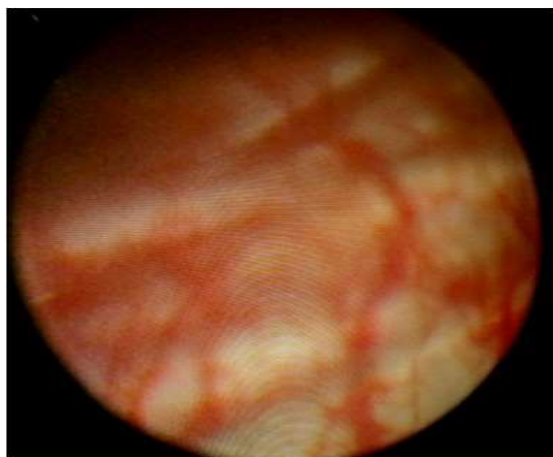
**Case report**

Seven-year old boy, with repeated infections of the urinary tract since his first years of life was first seen in our service. Had no dysuria or pollakiuria, no diurnal losses of urine, however, presenting nocturnal enuresis. He was hospitalized twice for abdominal pain thought as acute appendicitis. Never had hematuria. Physical exam was normal, US exam showed a trabeculated bladder wall, with bladder capacity of approximately 200 mL and 30 mL of post void residue. Voiding urethrocytography revealed good capacity of the bladder and, in the voiding phase, an image of failure in the filling of the posterior urethra,

with no vesicoureteral reflux (Fig. 1A, B). He had an urethroscopy that showed trabeculated bladder walls (Fig. 2) and numerous small polyps located in the area around the verumontanum (Fig. 3). Underwent electrofulguration of the polyps and developed well throughout the uneventful first year following the procedure; showed improvement in the nocturnal loss of urine, with a few occasional leakages. Since the polyps were placed in the area around the verumontanum and a possible biopsy was difficult to access, enough samples could not be obtained for histopathological evaluation. The patient did not have any complaints during one year follow-up.



**Fig. 1A, B.** Voiding urethroscopy showing the area with a filling failure in the posterior urethra (arrow).

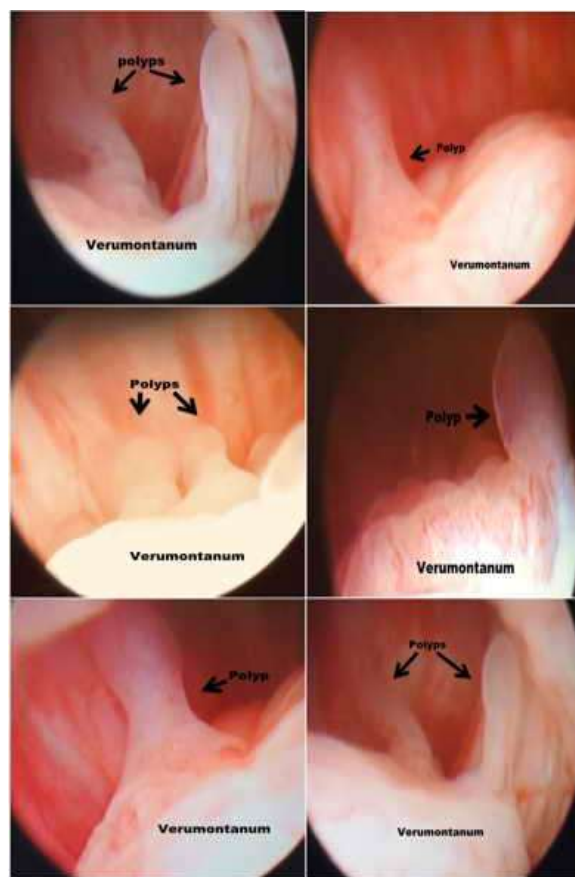


**Fig. 2.** Cystoscopy image showing trabeculated bladder walls.

## Discussion

Congenital posterior urethral polyps, also known as fibroepithelial polyps, although rare, are the most common benign mesodermal tumors of the urinary tract [3]. The embryological base for the appearance of such polyps is not clear; they are likely to be growths from mesonephric remnants that may even protrude through the urethral wall, provided the stalk is sufficiently long [5].

The polyps located in the posterior urethra may cause symptoms related to reduced urine flow, making it intermittent, causing sudden pain, hematuria and dysuria [3]. Since they are a mechanical impediment to the passage of urine, they actually alter the normal voiding cycle that, like in our patient, may lead to repeated infections of the urinary tract.



**Fig. 3.** Polyps present in the area around the verumontanum.

Our patient had two acute abdominal pain events that were most likely connected with the obstruction of the urinary flow, but that, at the time, were misinterpreted as an acute abdominal condition. Besides the urinary infection events our patient had nocturnal enuresis resistant to the drug treatment. Currently there is a trend towards considering enuresis as a disease that involves three main elements: a lower micturition triggering threshold, nocturnal polyuria, and nocturnal detrusor overactivity, believed to probably have been the factor that triggered the symptom in our patient [6].

Histologically the polyps are made up of vases, muscles and, less frequently, of nerves and glands lined with urothelium [3]. Since they were located in the area around the verumontanum, of difficult access for a possible biopsy, and given the certainty that they were benign tumors, we chose endoscopic electrofulguration that enabled the lesions to be excised and, as a result, the symptoms to disappear. Since we only have one year of follow-up, we intend to perform endoscopic exams, but our patient, after the treatment, has not yet had any symptoms.

Although a rarity, upon a condition of repeated infections of the urinary tract, one should consider the possible presence of congenital urethral polyps, do a diagnostic urethroscopy, and treat the polyps with electrofulguration.

### Compliance with ethical statements

*Conflicts of Interest:* None.

*Financial disclosure:* None.

*Consent:* All photos were taken with parental consent.

### References

- [1] Walsh PJ, Wiener JS. Urethral polyp presenting in a male infant with hematuria and urinary retention. *Urology.* 1999; 54(5):921–22.
- [2] Kesan KV, Gupta RK, Kothari P, Gupta A, Mudkhedkar K, Kamble R, et al. Posterior urethral polyp with type I posterior urethral valves: a rare association in a neonate. *Urology.* 2014;83(6):1401-3.
- [3] Akbarzadeh A, Khorraminouz R, Kajbafzadeh AM. Congenital urethral polyps in children: report of 18 patients and review of literature. *J Pediatr Surg.* 2014; 49(5):835-39.
- [4] Jain P, Shah H, Parelkar SV, Borwankar SS. Posterior urethral polyps and review of literature. *Indian J Urol.* 2007;23(2):206-7.
- [5] Bagley FH, Davidson AI. Congenital urethral polyp in a child. *Br J Urol.* 1976; 48(4):278.
- [6] Wodiani MR, Gasparini TR, Meyer KF, Freitas Filho LG. Would the association of different therapeutic agents be the Best solution for the treatment of nocturnal enuresis?. *JOJ Uro & Nephron.* 2019;6(3): 1-5.

Access this article online

<http://pediatricurologycasereports.com>

Quick Response Code

